

## Evaluation of Obturation by Image Analyses and Macrogol and Propylene Glycol Penetration

Nunéz P. Phides D.D.S., Ph.D. and Etsuro Hoshino, D.D.S., Ph.D.

Oral Ecology in Health and Infection, Niigata University Graduate School of Medical and Dental Sciences, Niigata, Japan

### Abstract

**Objectives:** This study aimed to evaluate obturations using radiographs and micro-computed tomography (MCT) and to determine if macrogol and propylene glycol could penetrate obturations until the apex.

**Method:** 30 extracted single-canal incisors were obturated with gutta-percha plus root canal sealer. Obturation was evaluated with radiographs and MCT using a scoring system (1-4) where a lower score means a better obturation. Dye mixed with macrogol and propylene glycol was applied to see whether it could penetrate through the obturation to the apex.

**Results:** MCT images often demonstrated voids not shown in the radiographs. 26 out of 30 samples had higher MCT scores (mean= 3.1; SD= ± 0.8) than radiographic scores (mean= 1.8; SD= ± 0.8). The dye-macrogol-propylene glycol mixture penetrated the obturation and exited through the apical foramen in all samples.

**Conclusion:** Obturation defects that were not shown by radiographs were often revealed by MCT. The dye-macrogol-propylene glycol mixture may have passed through those defects to the apex.

### Key words:

Image analysis, micro-computed tomography (MCT), root canal obturation

### Introduction

It is important to evaluate root canal obturation because inadequate obturation may not only produce areas where bacteria may remain and survive (1), but also provides routes through which bacteria may migrate to the periradicular tissues. Radiographs have often been used to examine root canal systems and evaluate obturations of the root canal, partly because of its non-destructive nature (2). However, radiographs often cannot detect voids and other minor obturation defects (3). They only show a two-dimensional picture, and may be quite inadequate considering current knowledge of root canal complexities (4-5). Aside from radiographs, another non-destructive method to study root canals is micro-computed tomography (MCT), which is capable of producing three-dimensional images (6). In this study, we used MCT to show obturation defects that may be undetected by radiographs.

As mentioned earlier, voids within an obturation may become areas for bacteria to thrive which may then become a source of re-infection of the canal. Such endodontic failures would then routinely undergo re-treatment based on the attending clinician's best judgement. A possible alternative treatment for such cases is Lesion Sterilization and Tissue Repair (LSTR) therapy. The basic concept of this therapy is the elimination of the cause of infection, in this case bacteria, by introducing the appropriate antibacterials into the tooth thereby resulting in disinfection of the lesion and resolution of inflammation. The main component of LSTR therapy is a macrogol-propylene glycol-antibiotic mixture (3Mix-MP) which has been used as an endodontic treatment for both primary and permanent teeth successfully (7-8). The ability of propylene glycol to penetrate an unfilled tooth has been shown by Cruz et al (9). However, it has not been demonstrated whether those vehicles could penetrate an obturated canal. In this study, we used a mixture of dye with macrogol and propylene glycol (MP). We substituted the dye

for the antibiotics to see whether such mixture would be able to penetrate an obturated canal thus testing the efficiency of MP as a vehicle to carry antibiotics within a filled canal.

This study aimed to evaluate root canal obturation by detection of defects with the use of radiograph and MCT. A second aim was to determine whether MP could penetrate the obturation to the apex.

### Materials and Methods

#### Sample preparation

A total of 30 single-canal incisors with fully-formed roots was selected from a pool of extracted teeth; the histories of which could not be determined. Each tooth was cut with a diamond disk about 1 mm coronal to the cemento-enamel junction. An initial apical file with stopper was inserted into the root canal until its tip could be seen at the apical foramen then withdrawn 1 mm. The distance from the stopper to the tip of the file was measured with an endodontic ruler and this was considered as the working length. After the root canal was enlarged with hand instruments (K-files) up to file size 40, the canal was then irrigated alternately with NaClO and water, and then obturated with gutta-percha using cold lateral condensation technique with Canalis® (Showa Shizai Kako Co., Ltd., Tokyo, Japan) containing zinc-oxide and eugenol as sealer. The samples were then kept for two weeks in 100% humidity to keep from dehydration while allowing for complete setting of the sealer.

#### Radiographic and MCT examination

Radiographs and MCT images of the root canal fillings were evaluated by two scoring methods. The first method (10), as modified, is shown in Table 1. Minimal detection level was set at 0.25mm as the least dimension of radiolucency that can be seen by the naked eye on an x-ray film. For the second scoring method (11), the root canal was divided into four sections from the apex to the orifice, with the apical area

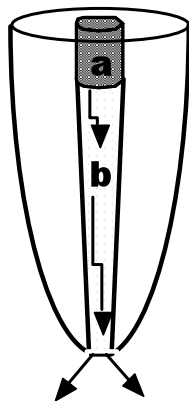
as the first section. Each section was scored either with 0 (no voids, indicated with a negative sign) or with 1 (with voids, indicated with a positive sign), regardless of the size or number of voids. The score for each sample was the sum of the scores of each root section. For both scoring systems, a low score, such as 1 or 2 (+ or ++ for the second scoring method), meant a well-obtured canal with minimal defects. MCT (Nittetsu Elex, Osaka, Japan) was operated as follows: pixel matrix: 256 x 256 x 256; slice thickness: 21 μm; projection number: 600 x 32; magnification: x 3.88; voltage: 60 - 70 kV; electrical current: 0.1 mA. Individual images were reconstructed by using a software program (NDTView, Sony, Tokyo, Japan; 3D bone for WinNT, Ratoc System Engineering, Tokyo, Japan). Root canal fillings were evaluated three-dimensionally from the labial, lingual, mesial, and distal aspects, so that for each radiographic score (RS) there were four corresponding MCT scores (MCTS). The average of the four scores was considered as the MCTS.

**Table 1.** First scoring method for evaluation of root canal obturation.

Score	Description
1	Well condensed - no or few minute voids (0.25 mm in diameter or length) with good adaptation to canal walls
2	Imperfectly condensed- with voids or defects found between obturation materials and canal walls more than 0.25 mm but less than 1 mm
3	Insufficiently condensed- with voids or defects found between obturation materials and canal walls 1 mm to 2 mm.
4	Poorly condensed- with voids or defects found between obturation materials and canal walls more than 2 mm.

**Dye + MP penetration test**

To show whether macrogol and propylene glycol (MP) could penetrate the obturated canals, a 2-3 mm deep cavity was



**Figure 1.** Schematic illustration of specimen for dye penetration test. (a) Dye + MP; (b) Gutta-percha + sealer; Arrows indicate passage of dye + MP.

prepared at the orifice of the filled root canals. A dye mixture consisting of MP, mixed at a 1:1 ratio was added to red food dye (Tokyo Kasei Kogyo Co., Ltd., Tokyo, Japan) and placed into the cavity which was then sealed with Cavition (GC Asahi Corp., Aichi, Japan), as shown in Figure 1. For the controls, dye mixed with water was used. Each tooth was placed on separate tubes which had white paper packed at the bottom. Care was taken to ensure contact between the root tip and the paper so that any dye exiting from the apical foramen would be absorbed into the white paper. The time that elapsed from dye application until dye penetration through the apex was recorded. A pink color observed at the apical foramen was considered as positive dye penetration.


**Statistical Analysis**

To determine if the differences between the RS and MCTS were significant, the Student's t-test was used. To determine whether there was a correlation between number of voids and speed of dye penetration, we used the Spearman Rank analysis.

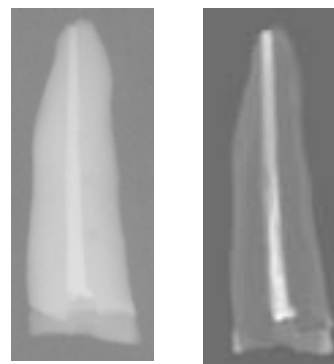
**Results**

**Radiographic and MCT examination**

Figure 2 (left) shows defects or voids as detected on radiographs. MCT produced a more porous image when the same obturation was examined (Fig. 2, right).



**Figure 2.** Radiographic and MCT images of defects within an obturation. (Left) Radiograph showed obturation defects. (Right) MCT showed larger defects on the same obturation.



**Figure 3.** Radiographic and MCT images of an obturated tooth. (Left) Radiograph showed no obturation defects. (Right) Same obturation had defects when evaluated by MCT.

For some well-obtured samples where no defects were observed on radiographs, such as the one shown on Figure 3 (left), defects were revealed when the same obturation was visualized with MCT (Fig. 3, right).

As shown in Table 2, radiographic scores (RS) for the first scoring method (n = 30; mean 1.83 ± 0.75 SD) were

significantly lower ( $P < 0.0001$ ) than MCT scores (MCTS) (mean  $3.10 \pm 0.80$  SD). This means that MCT could detect obturation defects more efficiently than radiographs. Similar results were obtained with the second scoring method where RS (mean  $1.87 \pm 1.28$  SD), were significantly lower than MCTS (mean  $3.47 \pm 0.73$  SD). This was also demonstrated with the tally of the number of teeth with the same score evaluated by radiographs and MCT (Table 3). Twenty-four out of 30 samples (for the first scoring method) and 20 out of 30 samples (for the second scoring method) had RS no higher than "2". In six samples, the defects were detected only with MCT, and not by radiographic evaluation (Table 3).

It should be noted that not all samples had a higher MCTS than RS, indicating that radiographs could show defects depending on the size and orientation of the said defects.

#### Dye + MP Penetration

Dye + MP mixture penetrated through obturation and exited to the root apex in each of all 30 samples tested. The mean time of dye exit was 48 hours ranging from 0.5 hour to 120 hours. However, dye exit time was not correlated to the obturation scores (Table 1; Spearman rank;  $P = 0.758857$ ;  $r_s = 0.0585$ ). For the controls, where dye was mixed with water, dye did not exit to the apex in almost all cases (Table 2).

Sample	Scoring Method 1		Scoring Method 2		Dye Penetration	
	RS	MCTS	RS	MCTS	MP +Dye	water +Dye
1	2	3	++	+++	+	-
2	1	1	+	C+	+	-
3	2	4	+++	++++	+	-
4	2	4	++++	++++	+	-
5	3	4	+++	++++	+	-
6	2	4	+++	++++	+	-
7	1	3	-	++++	+	+
8	1	3	++	++++	+	-
9	1	2	+	++	+	-
10	2	3	+	++++	+	+
11	2	3	++	++++	+	+
12	2	4	+++	++++	+	-
13	3	3	++	++	+	-
14	1	3	-	+++	+	-
15	2	4	++++	++++	+	-
16	2	3	+++	+++	+	-
17	2	3	++	++++	+	-
18	2	4	++	++++	+	-
19	2	3	+++	++++	+	-
20	1	2	+	++++	+	-
21	1	3	-	++++	+	-
22	1	2	+	+++	+	-
23	1	2	-	++	+	-
24	1	3	-	+++	+	-
25	1	3	-	++++	+	-
26	3	4	+++	++++	+	-
27	3	3	++	+++	+	-
28	3	4	++++	++++	+	-
29	2	2	++	+++	+	-
30	3	4	++	+++	+	-

**Table 2.** Radiographic (RS) and Micro-CT scores (MCTS) and dye penetration

Scoring details are explained in the text, Materials and Methods section.

Low score: good obturation; High score: poor obturation.

-: No visible dye penetration through the apex.

## Discussion

It has been demonstrated that radiographs may not always present an accurate picture of the actual condition of a root canal (12) partly because radiographs show only a two-dimensional image, so that some areas in the root canal are not visualized. By the same analysis, it can be assumed that radiographic images of a filled root canal do not give an accurate image of the true condition of the fillings. Defects or

voids located in areas not accessible to the x-rays are thus obscured from the naked eye of the clinician evaluating an obturation. MCT, on the other hand, is a method that has been used by many researchers to evaluate the anatomy of the root canal system both before and after instrumentation (13), and has been shown to give a high accuracy in terms of reproducing images of the outer surfaces of teeth as well as the interior parts including the root canal space (14). It has been demonstrated that MCT could produce images of root

canals filled with gutta percha that have a high correlation to histological sections (15).

In the present study, obturations were evaluated with radiographs and MCT. Root canals of most samples seemed to be better-obtured based on radiographic evaluation. Some defects that were undetected in the radiographic images were revealed in the MCT scans. In this study obturation was done in our hands, in vitro,

**Table 3.** Root canal obturation condition.

Score	Number of Teeth			
	Scoring Method 1		Scoring Method 2	
	RS	MCTS	RS	MCTS
0	---	---	6	0
1	11	1	5	0
2	13	5	9	4
3	6	14	7	8
4	0	10	3	18
	30	30	30	30

Scoring details are explained in the text, Materials and Methods section. Low score: good obturation; High score: poor obturation.

RS- Radiographic score;

MCTS- Micro-CT score;

Score 0 is applicable only to Scoring Method 1.

so that it was reasonable that radiographs showed rather good root canal obturation. Despite that, however, MCT images revealed quite a number of obturation defects hidden in radiographic evaluation. The results of this study suggest that the inherent limitations of radiographic images must not be overlooked.

The detection of voids is important as it has been established that adequate filling of the canal space after instrumentation is one of the essentials for the success of root canal therapies. However, successful root canal treatments in general suggest that the presence of defects may not always lead to endodontic failures. Still, it is possible that obturation defects may serve as niches where viable microorganisms may lodge. In addition, when those defects form continuous structures to the apex, they may provide a route for the migration of microorganisms to the periradicular tissues thus causing re-infection of the canal or the periradicular areas. Some studies have concluded that some bacteria may persist in the root canal even after obturation as a result of inadequate canal preparation and debridement, and apical or coronal leakage through defective restorations (1, 16). Such persistent bacteria have often been cited as the cause of most endodontic failures, rather than whether the root canal was satisfactorily obtured or not (17), warranting the need for a re-treatment of the tooth.

Conventional re-treatment often means removal of the old filling, re-cleansing and sometimes re-preparing the root canal (18). Depending on various factors, success of endodontic re-treatments range from moderate to high levels although there has been no general agreement as to decision-making when it comes to the clinical management of endodontic retreatment cases (19). One possible approach, a non-invasive pulpal treatment, also known as Lesion Sterilization and Tissue Repair (LSTR), involves the use of antibacterials combined with a mixture of macrogol and propylene glycol (MP) as the efficient vehicle to carry the antibacterials within the tooth (20). This antibacterial mixture (3Mix-MP) has been used successfully as an alternative form

of treating teeth with deep-seated carious lesions or even with periapical lesions (21).

In this study, we tested whether MP would be a good carrier of the antibacterial mixture within an obtured canal. We hypothesized that defects within an obturation may form continuous channels to the apex that may allow passage of MP. To determine this, we let MP penetrate the obturation by performing a dye penetration test. We substituted a dye that was completely soluble in MP for the antibacterials to visualize the MP clearly. Since the dye mixture exited through the apex in all the samples, we have shown that it was possible for MP to penetrate even the minute voids present in obturation. There was, however, no correlation between the speed of dye penetration and obturation scores. This may mean that much finer-sized gaps and spaces within the obturation that cannot be detected by radiographs or MCT contributed to constitute tunnel structures together with the larger-sized defects. This may indicate that some obturation defects were connected to each other and may have formed labyrinthine structures to the root apex. An obturation with labyrinthine structures is actually beneficial and contributes to the success of the treatment because they may trap any remaining microorganisms within the filling and prevent them from moving to the periradicular areas. However, trapped bacteria may, after some time, eventually find their way to the periapical areas. These rare cases may ultimately lead to endodontic treatment failure and would be indicated for re-treatment.

For the controls in this experiment, dye mixed with water did not exit through the apex in almost all samples. This may be due to the water's surface tension or hydrophobic components of the obturation materials, making it difficult for water to pass through. Cruz et al. have shown that water could not penetrate an unobtured canal as efficiently as propylene glycol, one of the components of MP (9).

Although inconclusive, it must be noted that the mixture of MP may have been essential to the consistent penetration of the dye mixture to the apex. This may suggest that MP could be a good vehicle to carry the prescribed antibacterials within a filled root canal. Being such, the antibacterials + MP mixture (3Mix-MP) need only be placed at the orifice of the canal and allowed to penetrate the obturation. By following the prescribed protocol of LSTR therapy, it may be possible to perform an endodontic re-treatment without having to remove the existing obturation. Researches have been and are still presently being conducted to investigate the possibility for such form of treatment to be considered as a possible alternative endodontic re-treatment procedure for certain endodontic failures especially those which are deemed to be caused by viable bacteria remaining within a filled canal (22-23).

### Acknowledgments

This research has been supported by Grants-in-Aids for Scientific Research 1440628 and 17390500 and JSPS Joint Research Projects 151075 and 151076.

### References

1. Sundqvist G, Figdor D, Persson S, Sjogren U: Microbiologic analysis of teeth with failed endodontic treatment and the outcome of conservative re-treatment. *Oral Surgery Oral Medicine Oral Pathology Oral Radiology and Endodontics* 1998; 85: 86-93.
2. Bellizzi R: Radiographic evaluation of root canal anatomy of in vivo endodontically treated maxillary premolars. *Journal of Endodontics* 1985; 11: 37-9.

3. Siqueira Jr JF: Aetiology of root canal treatment failure: why well-treated teeth can fail. *International Endodontic Journal* 2001; 34: 1-10.
4. Kasahara E, Yasuda E, Yamamoto A, Anzai M: Root canal system of the maxillary central incisor. *Journal of Endodontics* 1990; 16: 158-61.
5. Omer OE, Al Shalabi AI, Jennings M, Glennon J, Claffey NM: A comparison between clearing and radiographic techniques in the study of the root canal anatomy of maxillary first and second molars. *International Endodontic Journal* 2004; 37: 291-6.
6. Rhodes JS, Pitt Ford TR, Lynch JA, Liepins PJ, Curtis RV: Micro-computed tomography: a new tool for experimental endodontology. *International Endodontic Journal* 1999; 32:165-172.
7. Iwaku M, Hoshino E, Kota K: Lesion sterilization and tissue repair (LSTR) therapy: new pulpal treatment. How to conserve infected pulps. Tokyo, Japan: Nihon-Shika Hyoron, 1999
8. Takushige T, Cruz EV, Moral AA, Hoshino E: Endodontic treatment of primary teeth using a combination of antibacterial drugs. *International Endodontic Journal* 2004; 37: 132-8.
9. Cruz EV, Kota K, Huque J, Iwaku M, Hoshino E: Penetration of propylene glycol into dentine. *International Endodontic Journal* 2002; 35: 330-6
10. Kersten HW, Wesselink PR, Van Velzen SKT: The diagnostic reliability of the buccal radiograph after root canal filling. *International Endodontic Journal* 1987; 20: 20-4.
11. Beyer-Olsen EM, Orstavik D, Eriksen HM: Radiographic voids and leakage along root fillings in vitro. *International Endodontic Journal* 1983; 16: 51-8.
12. Van der Sluis LWM, Wu MK, Wesselink PR: An evaluation of the quality of root fillings in mandibular incisors and maxillary and mandibular canines using different methodologies. *Journal of Dentistry* 2005; 33: 683-8.
13. Dowker SEP, Davis GR, Elliott JC: X-ray microtomography – Nondestructive three-dimensional imaging for in vitro endodontic studies. *Oral Surgery Oral Medicine Oral Pathology Oral Radiology and Endodontics* 1997; 83: 510-6.
14. Bjorndal L, Carlsen O, Thuesen G, Darvann T, Kreiborg S: External and internal macromorphology in 3d-reconstructed maxillary molars using computerized x-ray microtomography. *International Endodontic Journal* 1999; 32: 3-9.
15. Jung M, Lommel D, Klimek J: The imaging of root canal obturation using micro-CT. *International Endodontic Journal* 2005; 38: 617-26.
16. Nair PN, Sjogren U, Krey G, Kahnberg KE, Sundqvist G: Intraradicular bacteria and fungi in root-filled, asymptomatic human teeth with therapy-resistant periapical lesions: a long-term light and electron microscopic follow-up study. *Journal of Endodontics* 1990; 16: 580-8.
17. Lin LM, Rosenberg PA, Lin J: Do procedural errors cause endodontic treatment failure? *Journal of the American Dental Association* 2005; 136: 187-193.
18. Mandel E and Friedman S. Endodontic retreatment: A rational approach to root canal reinstrumentation. *Journal of Endodontics* 1992; 18: 565-9.
19. Aryanpour S, Van Nieuwenhuysen JP, D'Hoore W: Endodontic retreatment decisions: no consensus. *International Endodontic Journal* 2000; 33: 208-18.
20. Hoshino E and Takushige T: LSTR 3Mix-MP method- better and efficient clinical procedures of lesion sterilization and tissue repair (LSTR) therapy. *Dental Review* 1998; 666: 57-106.
21. Ozan U and Er K: Endodontic treatment of a large cyst-like periradicular lesion using a combination of antibiotic drugs: A case report. *Journal of Endodontics* 2005; 31: 898-900.
22. Nakahara H, Takushige T, Hoshino E: Clinical evaluation of Lesion Sterilization and Tissue Repair (LSTR) 3Mix-MP endodontic treatment. Report presented at the 83<sup>rd</sup> General Session of the IADR, 2005.
23. Takushige T and Hoshino E: Clinical evaluation of pulpitis and root canal treatment using 3Mix-MP. Report presented at the FDI Annual World Dental Congress, 2007.